

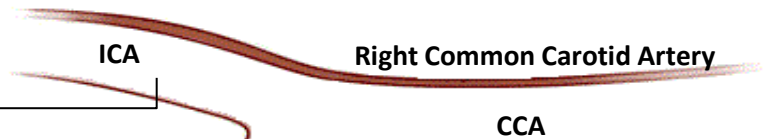


Carotid Duplex Report

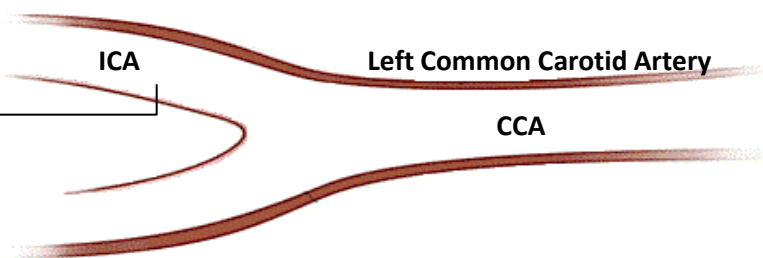
Patient Name: BEAL, STUART
DOB: 6-Jun-66

Physician: RASTOGI
Exam Date: 3-Aug-23

Right	ICA	CCA
*PSV:	38	55
*EDV:	27	23
RICA STENOSIS:	< 20%	



Left	ICA	CCA
*PSV:	77	90
*EDV:	29	27
LICA STENOSIS:	< 20%	



Left Vertebral Artery
Velocity: N/V
Direction: Antegrade

Right Vertebral Artery
Velocity: N/V
Direction: Antegrade

Vertebral Artery



COMMENT: Dynamic ultrasound scanning of the neck was performed with carotid duplex (Doppler & B-Mode ultrasound) arterial analysis including color flow and spectral analysis; Impression: Normal bilateral carotid duplex ultrasound exam. Unable to obtain bilateral vertebral artery images due to patient body habitus.

Physicians Signature: _____



